

# Single-operator cholangioscopy is useful for visual assessment of bile duct pathology

Finnur Mellemsgaard, Rune B. Strandby, Julie Blockmann, Steen C. Kofoed, Lars B. Svendsen & Michael P. Achiam

## SUMMARY

**INTRODUCTION:** Single-operator cholangioscopy (SOC) is increasingly used for evaluation of the biliary tree following endoscopic retrograde cholangiopancreatography (ERCP). This study aimed to determine the visual and histological success rates of SOC at a single Danish tertiary referral centre.

**METHODS:** All patients undergoing SOC between 2008 and 2015 were retrospectively included from a prospectively maintained database. Patient characteristics and procedure-related variables were obtained from medical records. A visual and a histological success rate were determined according to predefined criteria.

**RESULTS:** In total, 54 patients underwent SOC, most often due to suspicion of malignancy ( $n = 53$ ; 98%). In one case, access to the common bile duct failed, and in six cases malignant disease was missed. Thus, the cholangioscopies were successful in 47 of 54 procedures corresponding to a visual success rate of 87%.

Nine patients (17%) had a mean of  $1.3 \pm 1.0$  SOC-guided biopsies taken. The extracted tissue was inadequate for histological evaluation in seven of nine cases, corresponding to a histological success rate of 22% (two out of nine tissue samples were eligible for histological diagnosis).

**CONCLUSIONS:** Considering the reasonable visual success rate, SOC seems to be a useful extension of ERCP during diagnostic work-up for detection of malignant disease in the biliary tree. However, one biopsy per patient is insufficient for histological verification of common bile duct malignancy.

**TRIAL REGISTRATION:** The Danish Health Authority (3-3013-1299/1) and The Danish Data Protection Agency (RH-2015-229).

**FUNDING:** none.

Endoscopic retrograde cholangiopancreatography (ERCP) is commonly used for initial evaluation of biliary tree strictures including tumours, inflammation and biliary stones [1]. The drawbacks of ERCP, however, are that inspection of the biliary ducts is performed indirectly from a cholangiogram displayed by X-rays. Also, tissue biopsies from lesions within the biliary ducts are obtained by brush cytology, and for this method a sensitivity below 60% has been reported for the diagnosis of malignant biliary lesions [2, 3].

Peroral cholangioscopy has been performed since 1975. Contrary to ERCP, this allows the operator to assess the pancreatic and biliary ducts visually [4]. However, the procedure was not widely used because the first cholangioscopes on the market were expensive, fragile and required two operators [5]. In 2007, Boston Scientific launched a single-operator cholangioscopy (SOC) device named SpyGlass Direct Visualization System, which also allowed direct visualisation of the biliary ducts, and which only required one operator [6]. The platform consists of a reusable fibre optic probe for imaging (SpyGlass Direct Visualization Probe), which can be inserted through a disposable access and delivery catheter (SpyScope) attached to the duodenoscope. Through the catheter, irrigation of the biliary duct is possible and small tissue biopsies can be obtained through a separate working channel (SpyBite biopsy forceps).

Similarly to the ERCP, the main indications for SOC are evaluation of undetermined biliary duct strictures and removal of firmly lodged stones [7]. Studies have reported that Spyglass is feasible with procedure-related success rates of up to 97%, and SOC is fairly time-consuming in comparison with ERCP [8, 9].

The aim of this study was to evaluate the overall feasibility of SOC during a seven-year period at a tertiary Danish referral centre by determining the visual and histological success rates. Moreover, we examined whether or not visual SOC findings offered additional diagnostic information compared with tissue biopsies obtained by ERCP.

## METHODS

All patients who underwent SOC at a single Danish tertiary referral centre between 2008 and 2015 were identified by searching for specific procedure codes in the hospital's local database (Endobase). Initially, patient records were evaluated individually by two reviewers (FM, JB) and data were retrieved in two separate sheets. Then, data were reassessed in a joint session by two of the authors (RBS, FM) to rule out any discrepancies, and a final decision was made. The study was approved by The Danish Data Protection Agency (RH-2015-229) and the Danish Health Authority (3-3013-1299/1).

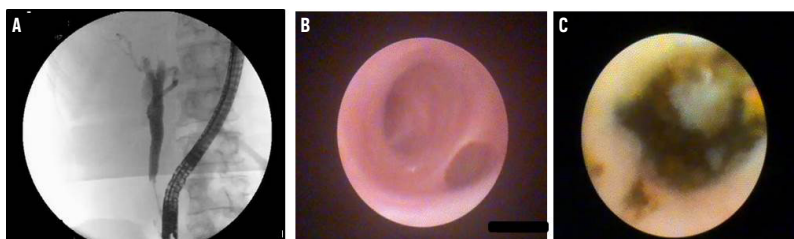
## ORIGINAL ARTICLE

Department of Surgical Gastroenterology, 2122, Rigshospitalet, Denmark

Dan Med J  
2018;65(8):A5496

 **FIGURE 1**

**A.** Cholangiography by endoscopic retrograde cholangiopancreatography. **B.** The biliary confluence visualised by single-operator cholangioscopy. **C.** Bile stone in the common hepatic bile duct visualised by single-operator cholangioscopy.



One experienced endoscopist performed all procedures. Firstly, an oesophagogastro-duodenoscopy was carried out under propofol sedation. Then, following cannulation of the major duodenal papilla, a catheter was placed in the common bile duct and a cholangiography was carried out by injection of a contrast agent (Omnipaque, GE Healthcare, Little Chalfont, UK). If indicated, biopsies or a brush cytology was obtained. SOC was performed with a reusable fibre optic probe (SpyGlass, Boston Scientific, Massachusetts, USA) capable of tip deflection at least 30° in four directions (**Figure 1**). The probe was introduced through a disposable access and delivery catheter (SpyScope, Boston Scientific, Massachusetts, USA) attached to the duodenoscope. The biliary duct was then inspected visually and, if required, the biliary duct was irrigated with sa-

line to optimise visibility. Tissue biopsies were obtained, if indicated by the endoscopist, using a 3-Fr forceps with a 4.1 mm jaw opening (SpyBite, Boston Scientific, Massachusetts, USA). For stone removal, an ERCP-guided basket or balloon was used.

The main outcome was the success rate of the SOC procedure defined as: 1) Achieved access to the common bile duct; 2) Adequate visualisation of target lesions; 3) No missed malignant lesions; 4) SOC-guided biopsies (if obtained) deemed adequate for histological evaluation by the pathologist [8]. The visual assessment of SOC was considered successful if requirements one to three were met. Likewise, histological assessment of SOC was considered successful if requirement four was fulfilled. In addition, an overall success rate including both visual and histological results was determined. Findings with SOC were categorised into three groups. “Malignant disease” was defined as either an obvious or a strong suspicion of malignancy, including undetermined biliary duct stenosis, papillomatosis, cholangiocarcinoma or intraductal papillary mucinous neoplasm. “Non-malignant suspicion” was defined as identification of biliary stones, stenosis without suspicion of malignancy or other benign abnormalities. Finally, “non-pathology” was defined as disease-free bile ducts as assessed by the endoscopist.

By decision of the endoscopist, some patients had ERCP-guided brush cytology and/or papillary biopsies from the major duodenal papilla obtained in addition to SOC. For these patients, histological findings from ERCP-guided biopsies were compared with SOC results.

Statistical calculations were carried out by SPSS (IBM SPSS Statistics for Windows, version 22.0, Armonk, NY, USA). For distribution of dependent variables, descriptive statistics was used.

## RESULTS

### Single-operator cholangioscopy

A total of 54 patients underwent SOC. Baseline characteristics are shown in **Table 1**.

The main indication for SOC was suspicion of malignancy (n = 53; 98%), but in one patient visual examination of the common bile duct following laparoscopic cholecystectomy was necessary. The visual SOC findings resulted in suspicion of: malignant disease in 13 (24%) patients, non-malignant disease in 25 (46%) patients and non-pathology in 15 (28%) patients (**Figure 2**). In one case, visibility was inadequate due to angulation of the common bile duct, and malignant disease was missed in six cases. Malignancy was, however, confirmed by diagnostic laparoscopy (n = 3) and by brush cytology (n = 3). Thus, a successful visual SOC evaluation was achieved in 47 out of 54 cases, corresponding to a visual success rate of 87%.

 **TABLE 1**

Baseline characteristics.

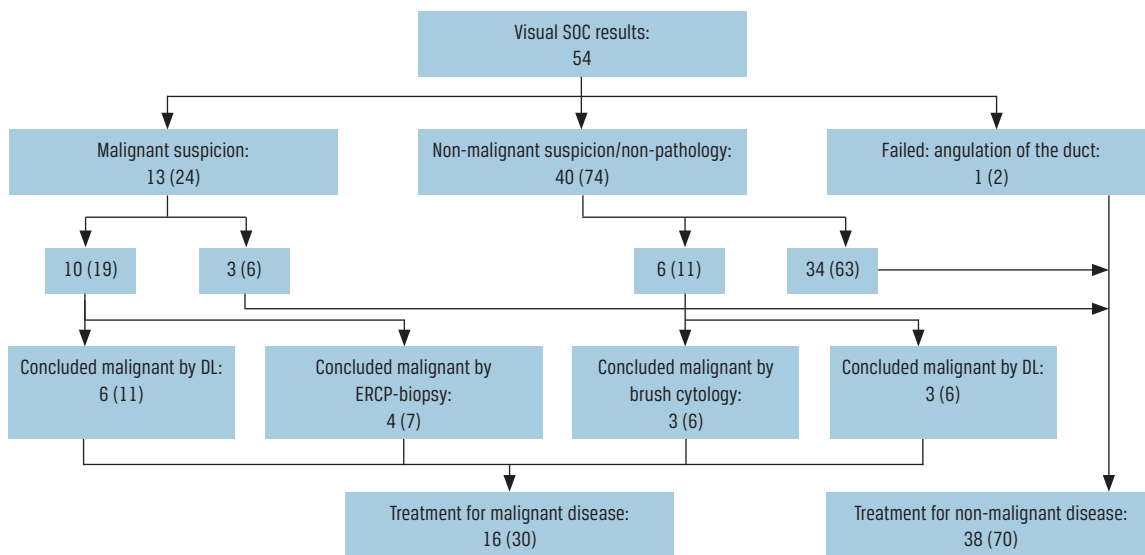
Male sex, n (%)	21 (39)
Age, yrs, mean ± SD	60 ± 14.1
ASA score, mean ± SD	2 ± 0.5
BMI, kg/m <sup>2</sup> , mean ± SD	25 ± 5.5
Tobacco: active & former use, n (%)	28 (52)
Alcohol: active & former abuse, n (%)	10 (19)

ASA = American Society of Anaesthesiologists; SD = standard deviation.

 **TABLE 2**

SpyBite biopsy summary. Values are n (%).

Biopsies	Patients	Successful procedures
1	6 (11)	0
2	2 (4)	1
4	1 (2)	1
Total	9 (17)	2 (22)

 **FIGURE 2**


DL = diagnostic laparoscopy; ERCP = endoscopic retrograde cholangiopancreatography; SOC = single-operator cholangioscopy.

A small number of patients ( $n = 9$ ; 16.7%) had SOC-guided biopsies obtained, and a mean of 1.3 (standard deviation:  $\pm 1.0$ ) biopsies were examined per patient (Table 2). However, the sampled tissue was inadequate for histological evaluation in seven out of nine cases, corresponding to a success rate of 22%.

Overall, 63 procedures were performed: 54 visual assessments with SOC and nine histological evaluations. In total, 49 of 63 procedures were successful yielding an overall success rate of 78%.

### Endoscopic retrograde cholangiopancreatography

In addition to SOC, 32 patients had ERCP-guided biopsies obtained as brush cytology from the common bile duct and/or tissue biopsies from the major duodenal papilla. The histological results comprised eight (25%) malignant cases, 22 (69%) non-malignant cases, and two cases (6%) that were inadequate for evaluation (Figure 3). In nine of the 22 cases where ERCP-guided biopsies indicated non-malignant disease, SOC gave rise to visible suspicion of malignant disease. Malignancy was eventually confirmed in five out of nine cases by diagnostic laparoscopy ( $n = 4$ ) and by CT/MRI ( $n = 1$ ). On the other hand, malignant disease was identified in three patients by ERCP-guided biopsies, where malignant disease was missed by SOC (Figure 3).

### Final treatment and complications

A total of 16 (30%) patients were treated for malignancy, including intended curative surgery ( $n = 10$ ; 2%), palliative chemotherapy or stent placement ( $n =$

3; 6%), and no treatment by patient request ( $n = 3$ ; 6%). Benign diseases ( $n = 13$ ; 24%) were treated with stone extraction via ERCP ( $n = 4$ ; 7%), stent placement ( $n = 5$ ; 9%), cholecystectomy ( $n = 3$ ; 6%) or balloon dilatation with ERCP ( $n = 1$ ; 2%). The remaining patients ( $n = 25$ ; 46%) received no treatment.

Following the SOC procedure, 11 (20%) patients had complications: haemorrhage ( $n = 1$ ; 2%), upper abdominal pain ( $n = 7$ ; 13%), fever ( $n = 2$ ; 4%) and vomiting and nausea ( $n = 3$ ; 6%). Two patients had more than one type of complication. Haemostasis was achieved with an ERCP-guided balloon and abdominal pain, fever, vomiting and nausea were treated successfully with analgesics or antibiotics. No patients developed post-procedural pancreatitis.

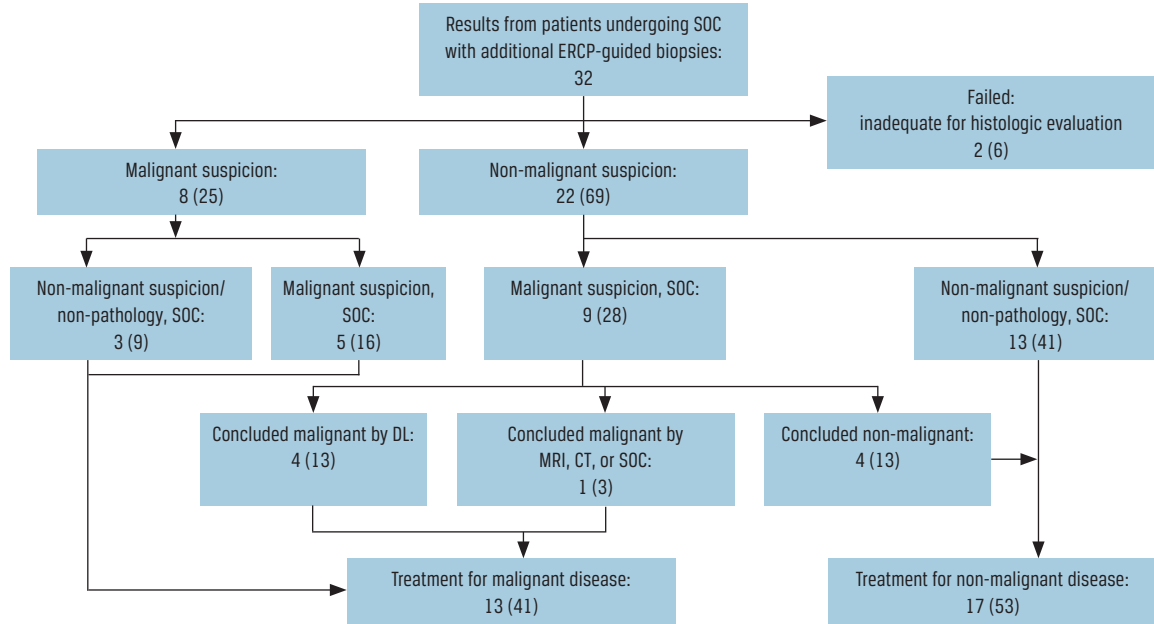
### DISCUSSION

This study found a visual success rate of 87% and a histological success rate of 22%, using SOC by a single experienced endoscopist, corresponding to an overall success rate of 78%.

Overall, the visual success rate found in this case series is in line with that of other studies, including a larger study with 297 patients, in which a visual success rate of 93% was reported [9]. Malignant disease was, however, missed in six cases (11.1%) during visible assessment with SOC in this study. Fortunately, these malignant tumours were detected with other diagnostic procedures, including ERCP-guided brush cytology ( $n = 3$ ) and diagnostic laparoscopy ( $n = 3$ ), indicating that visual assessment with SOC should not stand alone in clinical decision making. In contrast,

**FIGURE 3**

Results from patients undergoing single-operator cholangioscopy with additional endoscopic retrograde cholangiopancreatography-guided biopsies obtained by brush cytology and/or papillary biopsies from the major duodenal papilla. Values are number of patients (%).



DL = diagnostic laparoscopy; ERCP = endoscopic retrograde cholangiopancreatography; SOC = single-operator cholangioscopy.

malignant disease was identified in five patients with SOC in whom ERCP-guided biopsies were deemed non-malignant. Therefore, ERCP and visible SOC seem to support each other during endoscopic evaluation of the duodenum and common bile duct. Nevertheless, both SOC and ERCP lack sensitivity for detection of extra ductal disease, exemplified by the three patients in whom malignancy was missed endoscopically but confirmed during diagnostic laparoscopy.

In this study, nine patients had SOC-guided biopsies obtained, but only two tissue samples were adequate for histological evaluation, yielding a success rate of 22%. Of note, only one biopsy was obtained per patient on average and, consequently, our results should be interpreted with caution. At our institution, ERCP-guided brush cytology is the preferred modality for obtaining cells for histological evaluation, which probably explains the low number of tissue samples obtained with SOC. When tissue is collected, the SpyBite forceps have to be clutched completely together in order to withdraw the wire, including the very small amount of extracted tissue. In addition, repeating this procedure can be time-consuming. A study with 36 patients included an average of four SOC-guided biopsies per patient and reported a mean sampling time of 12 minutes, which accounts for approximately one fifth of the total procedure length [8]. For that reason, brush cytology may seem more feasible. Nevertheless, the histological success rate for SOC in other studies ranges between 70-100% [2, 10], with increasing success rates (88% or

above) when four or more biopsies are evaluated per patient [9]. Likewise, one study with 165 patients reported that obtaining at least four, versus less than four biopsies, increased the adequacy of the specimens (90% versus 64%) [11]. A new generation of SOC, SpyGlass DS Direct Visualization System released in 2015, is also believed to improve the diagnostic accuracy. Recent reports indicate that the diagnostic yield of malignant disease based on forceps biopsies has improved compared with the older generation of forceps used in this study [12, 13]. In addition, the SpyGlass DS is easier to set up and comes with an improved digital image with a 60% wider field of view [14]. Also, the device has the capability of suctioning to ease over-view.

In our series, procedure-related complications occurred in 11 patients (20%), and all were treated successfully. Other studies have reported a prevalence of complications ranging 3-10% [8], [12, 15]. The higher complication rate found in this study is probably related to the fact that 13% of the patients had complaints of abdominal pain following SOC. Since pain is a subjective measure and is to some degree expected following a procedure like ERCP and SOC, definitions of when pain should be considered a complication may differ among studies. Of note, in contrast to others, none of our patients developed pancreatitis after the procedure, and SOC generally seems to be a safe procedure with a complication risk equalling that associated with ERCP, i.e. 4-15% [16]. One study even found

that haemorrhage occurred more often during ERCP than SOC. The same study found no difference in the prevalence of pancreatitis, nor in overall complication risk [16]. In contrast, one study demonstrated that SOC may be associated with higher rates of cholangitis than ERCP [17]. This may be related to lengthier procedure times resulting in an increased amount of intraluminal air being inflated into the biliary duct besides saline used for irrigation causing further distention. Taken together, serious complications following SOC seem to be rare. Nevertheless, we think that SOC should be performed by trained endoscopists in specialised centres accustomed to handling SOC-related complications. In line with this, we are aware of eight centres in Denmark that perform SOC at this point, all possessing advanced endoscopic competence.

The strengths of this study include, firstly, complete registration of data. Since our institution started using SOC in 2008, all procedures have been registered prospectively. Therefore, we consider that the risk of selection bias is small. Secondly, one experienced endoscopist performed all procedures thereby reducing variability in operator-dependent variables like visual assessment. The main limitations of this study include the low number of included patients and, especially, the few SOC-guided biopsies available for histological assessment. This may reduce external validity. Also, we acknowledge that follow-up was limited to the time period around the SOC. Hence, patients considered with non-malignant disease could potentially have been re-examined months later and diagnosed with a cancer at that time. Therefore, one SOC/ERCP session may not be sufficient to rule out malignancy.

## CONCLUSIONS

A reasonable visual success rate can be achieved with SOC and the modality seems to be a useful extension of ERCP as part of the diagnostic work-up for detection of malignant disease in the common bile duct. For reliable histological results, a single biopsy of the suspected lesion is inadequate, but our low sample size does not allow us to conclude on the value of SOC-guided biopsies.

**CORRESPONDENCE:** Rune B. Strandby.  
E-mail: rune.broni.strandby.01@regionh.dk

**ACCEPTED:** 21 June 2018

**CONFLICTS OF INTEREST:** none: Disclosure forms provided by the authors are available with the full text of this article at [www.danmedj.dk](http://www.danmedj.dk)

## LITERATURE

- Hoffman A, Rey JW, Kiesslich R. Single operator choledochoscopy and its role in daily endoscopy routine. *World J Gastrointest Endosc* 2013; 5:203-10.
- Siddiqui AA, Mehendiratta V, Jackson W et al. Identification of cholangiocarcinoma by using the Spyglass Spyscope system for peroral cholangioscopy and biopsy collection. *Clin Gastroenterol Hepatol* 2012;10:466-71; quiz e48.
- Maydeo A, Kwek BE, Bhandari S et al. Single-operator cholangioscopy-guided laser lithotripsy in patients with difficult biliary and pancreatic ductal stones (with videos). *Gastrointest Endosc* 2011;74:1308-14.
- Kahaleh M. Spyglass direct visualization system. *Clin Endosc* 2012;45: 316-8.
- Chen YK. Preclinical characterization of the Spyglass peroral cholangiopancreatography system for direct access, visualization, and biopsy. *Gastrointest Endosc* 2007;65:303-11.
- Seelhoff A, Schumacher B, Neuhaus H. Single operator peroral cholangioscopic guided therapy of bile duct stones. *J Hepatobiliary Pancreat Sci* 2011;18:346-9.
- Parsi MA. Peroral cholangioscopy in the new millennium. *World J Gastroenterol* 2011;17:1-6.
- Draganov PV, Lin T, Chauhan S et al. Prospective evaluation of the clinical utility of ERCP-guided cholangiopancreatography with a new direct visualization system. *Gastrointest Endosc* 2011;73:971-9.
- Chen YK, Parsi MA, Binmoeller KF et al. Single-operator cholangioscopy in patients requiring evaluation of bile duct disease or therapy of biliary stones (with videos). *Gastrointest Endosc* 2011;74:805-14.
- Nagayoshi Y, Aso T, Ohtsuka T et al. Peroral pancreatoscopy using the SpyGlass system for the assessment of intraductal papillary mucinous neoplasm of the pancreas. *J Hepatobiliary Pancreat Sci* 2014;21: 410-7.
- Kalaizakis E, Webster GJ, Oppong KW et al. Diagnostic and therapeutic utility of single-operator peroral cholangioscopy for indeterminate biliary lesions and bile duct stones. *Eur J Gastroenterol Hepatol* 2012;24: 656-64.
- Pereira P, Peixoto A, Andrade P et al. Peroral cholangiopancreatography with the SpyGlass(R) system: what do we know 10 years later. *J Gastrointest Liver Dis* 2017;26:165-70.
- Ogura T, Imanishi M, Kurisu Y et al. Prospective evaluation of digital single-operator cholangioscope for diagnostic and therapeutic procedures (with videos). *Dig Endosc* 2017;29:782-9.
- Parsi MA, Stevens T, Bhatt A et al. Digital, catheter-based single-operator cholangiopancreatography: can pancreatoscopy and cholangioscopy become routine procedures? *Gastroenterology* 2015;149: 1689-90.
- Ramchandani M, Nageshwar Reddy D, Lakhtakia S et al. Role of single-operator per-oral cholangioscopy and intraductal US in assessment of portal biliopathy (with videos). *Gastrointest Endosc* 2014;79:1015-9.
- Hammerle CW, Haider S, Chung M et al. Endoscopic retrograde cholangiopancreatography complications in the era of cholangioscopy: is there an increased risk? *Dig Liver Dis* 2012;44:754-8.
- Sethi A, Chen YK, Austin GL et al. ERCP with cholangiopancreatography may be associated with higher rates of complications than ERCP alone: a single-center experience. *Gastrointest Endosc* 2011;73: 251-6.