

Original Article

Dan Med J 2020;67(4):A11200886

Sentinel lymph node mapping for endometrial and cervical cancer in Denmark

Sarah Marie Bjørnholt*^{1, 2}, Sara Elizabeth Sponholtz*^{3, 4}, Algirdas Markauskas³, Ligita Paskeviciute Frøding⁵, Christian Ribbjerg Larsen⁶, Katrine Fuglsang¹, Doris Schleder⁷, Ole Mogensen^{1, 2} & Pernille Tine Jensen^{1, 2, 4}

1) Department of Gynaecology and Obstetrics, Aarhus University Hospital, 2) Institute of Clinical Medicine, Faculty of Health, Aarhus University, 3) Department of Gynaecology and Obstetrics, Odense University Hospital, 4) Department of Clinical Research, Faculty of Health Science, University of Southern Denmark, 5) Department of Gynaecology and Obstetrics, Copenhagen University Hospital – Rigshospitalet, 6) Department of Gynaecology and Obstetrics, Copenhagen University Hospital – Herlev Hospital, 7) Department of Clinical Pathology, Odense University Hospital, Denmark

Dan Med J 2021;68(4):A11200886

ABSTRACT

INTRODUCTION: This was a surgical pilot study to systematically introduce the technique of sentinel lymph node (SLN) mapping in women with early-stage stage cervical cancer (CC) and endometrial cancer (EC) in Denmark. The study aimed to facilitate structured surgical training to ensure surgeon proficiency in SLN mapping. The study precedes two national prospective studies on the oncological safety and correct patient selection for SLN mapping in CC and EC.

METHODS: The study was conducted at four gynaecological cancer centres at Odense and Aarhus University Hospital, Rigshospitalet and Herlev Hospital, between September 2016 and August 2019. All centres went through a protocolled introduction to the surgical technique, pelvic lymphatic drainage, pathological ultra-staging and data entry. A criterion of a total (uni- and bilateral) SLN detection of > 80%, based on 30 SLN mappings was set.

RESULTS: The four centres performed 140 (range: 30-46) procedures. The total SLN detection rate was 91.3% with bilateral SLN detection in 68.8% and unilateral SLN detection in 22.5% of cases. The cumulated total SLN detection rate at three centres was above the pre-set 80% criterion from the beginning of inclusion, whereas one centre reached the criterion after 20 procedures.

CONCLUSIONS: In this study, all centres demonstrated international-level SLN detection rates within 30 procedures. Hence, all centres met the study criterion regarding surgeon proficiency and were eligible for the national studies.

Funding: Eva & Henry Fränkels Fond, Frimodt-Heineke Fonden, Kong Christian X Fond.

TRIAL REGISTRATION: The study was approved by the Danish Data Protection Agency (R. no.15/52037). The SENTIREC studies including this pilot study are registered with clinicaltrials.gov (NCT02825355 and NCT02820506).

This was a pilot study evaluating surgical training in the sentinel lymph node (SLN) mapping technique in women with early-stage stage cervical cancer (CC) and endometrial cancer (EC). The aim of the pilot study was to facilitate structured surgical training at the Danish gynaecological cancer centres to ensure surgeon proficiency in accurate SLN mapping before investigating the oncological safety of the technique in two large national studies.

SLN mapping in CC and EC is expected to have several advantages compared with radical pelvic

lymphadenectomy (PL). Since only a few lymph nodes are removed, the surgical procedure is shorter, and the rate of intra- and post-operative complications is expected to be lower. Another important advantage is the detection of small-volume lymph node metastases (LNM) [1] owing to the use of ultra-staging. Furthermore, the SLNs may be identified in areas, e.g. the para-aortic and pre-sacral area, which are not routinely examined with standard PL [2, 3].

SLN mapping is a surgical procedure with targeted identification of selected lymph nodes. In SLN mapping, the first lymph node to which the cancer drains is denoted the SLN. If the SLN is without metastatic disease, the following nodes are theoretically without malignancy. SLN mapping includes ultra-staging, a delicate pathological examination with serial sectioning and simultaneous immunohistochemical and haematoxylin/eosin (HE) staining of the SLNs. This allows for detection of micro-metastases and isolated tumour cells.

SLN mapping has proven safe in selected groups of patients with, e.g., vulva and breast cancer [4]. Here, the women benefit from reduced morbidity and increased sensitivity to detect LNM, owing to ultra-staging [5, 6].

Surgery is the standard treatment of early-stage CC and EC. Lymph node staging allocates women to adjuvant treatment in the case of LNM. Per se, radical PL has not demonstrated any survival benefit in either of the two cancers [7, 8]. However, adjuvant treatment improves survival in women with metastatic disease. From the histopathological profile of CC and EC, it is possible to predict subgroups with a high or low risk of metastatic disease, recurrence and death. For both cancers, emerging evidence and a strong rationale for the implementation of SLN mapping in groups with a low risk of metastases and recurrence exist, whereas the evidence in the groups with a higher risk remains limited.

This study preceded the initiation of two large national studies; the SENTIREC studies “Sentinel Lymph Node Mapping with Robotic Assisted Near Infra-Red Fluorescent Imaging in Women with Endometrial and Cervical Cancer”. To enrol in the national studies, each centre should successfully meet predefined criteria for SLN detection success and surgical set-up at centre level. Here, we present the outline and results of the pilot study.

METHODS

Study set-up

This study was conducted at four of five gynaecological cancer centres in Denmark: Odense University Hospital, Aarhus University Hospital, Rigshospitalet and Herlev Hospital, between September 2016 and August 2019. For administrative reasons, each centre had a different initiation date. All Danish gynaecological cancer centres were offered participation. Only centres who agreed to participate in the SENTIREC studies were enrolled in the pilot study.

Gynaecological cancer centres that undertake robotic assisted laparoscopic surgical treatment for CC and/or EC were eligible. All centres were thoroughly introduced to the SLN mapping technique at investigator meetings, and local co-investigators were appointed. Written and video material with clarification of the SLN procedure with indocyanine green (ICG) tracer injection, pelvic lymphatic drainage, locations of SLNs and a surgical algorithm were shared. Site visits were made before the study was initiated. Regular investigator meetings ensured the exchange of experiences, procedure adherence and continued proficiency training. Only named, experienced surgeons who performed robotic surgery and who were allocated to the gynaecological oncological team at each centre were included in the study. Based on the existing literature, a criterion of a total (uni- and bilateral) SLN detection of > 80% in a minimum of 30 SLN mapping procedures was set [9, 10].

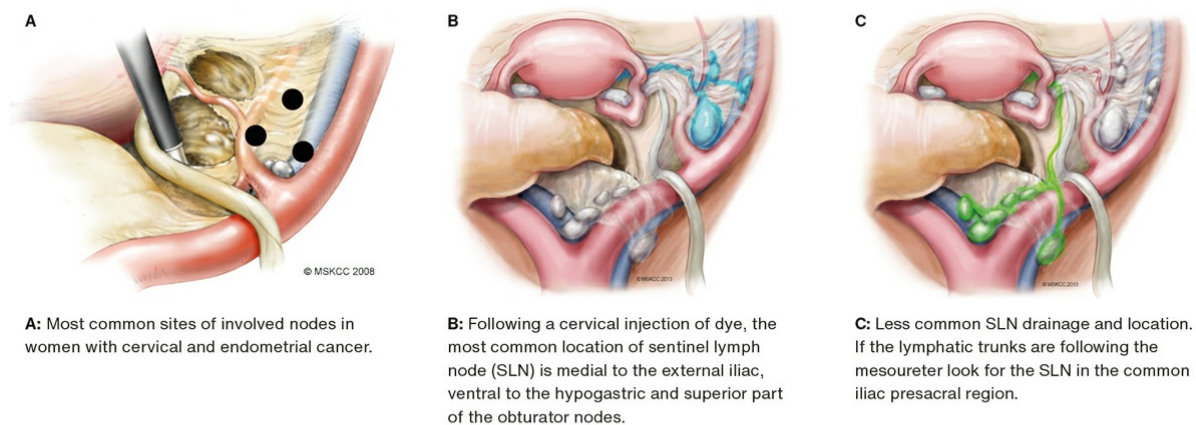
Patients

Procedures with women who underwent robotic laparoscopic surgical treatment for early-stage CC and EC were included. In this study, we refer to high-risk (HR) CC as cancers with a tumour size > 2 cm and to low-risk (LR) CC as cancer with a tumour size ≤ 2 cm [11]. For EC, we refer to HR EC in case of endometrioid adenocarcinoma grade 3 and non-endometrioid histology. The EC of low-intermediate risk (LIR) consists of endometrioid adenocarcinoma grade 1 and 2.

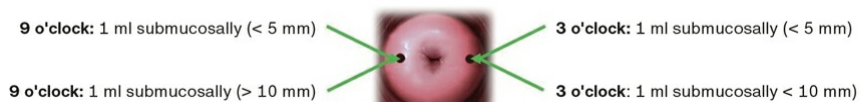Sentinel lymph node mapping procedure

With the patient anaesthetised, the ICG solution was injected into the cervix (**Figure 1**). During surgery, pelvic side wall spaces were exposed and all locations of pelvic lymph nodes were examined using the robotic near-infrared fluorescence imaging system. The first fluorescent hotspot in the lymph drainage pathways was denominated an SLN, and the anatomical location was noted (**Figure 2**). The surgeon was responsible for clear denomination of the locations of removed SLNs. After removal of SLNs, the standard surgery followed the Danish Gynaecological Cancer Group (DGCG) guidelines for CC and EC [12, 13]. Further lymph node removal was done at the surgeon's discretion.

FIGURE 1 Sentinel lymph node mapping.

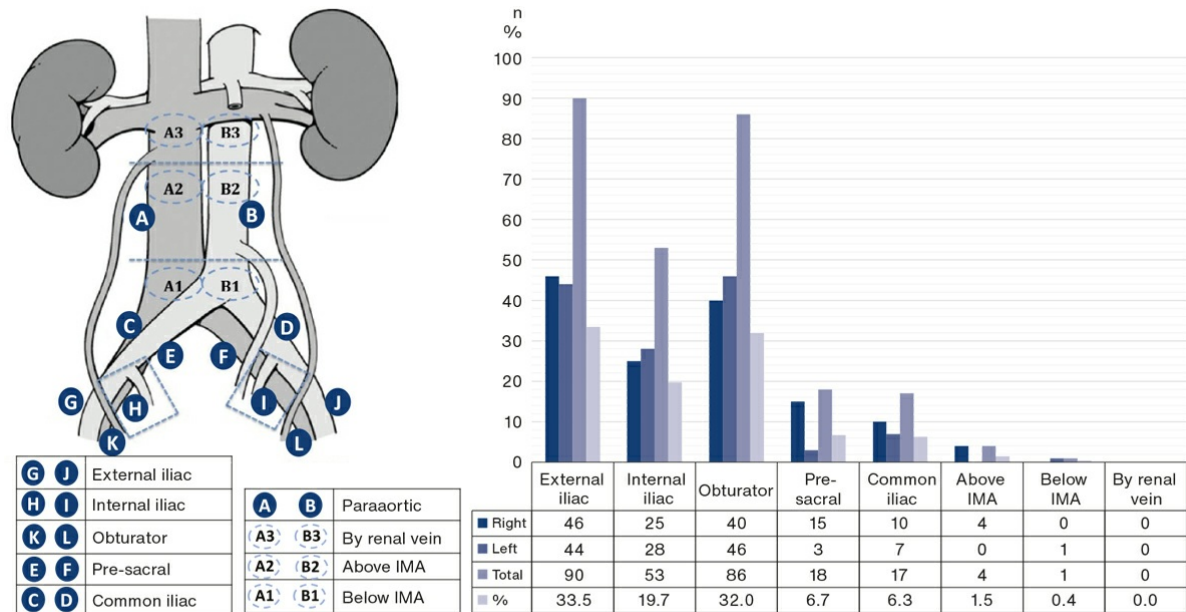


Reproduced with permission. ©2008/2013 Memorial Sloan Kettering Cancer Center.



The injection site for indocyanine green (ICG) used in this protocol. Immediately prior to surgery a 1.25 mg/ml ICG solution was injected into the cervix, as pictured.

FIGURE 2 Location of sentinel lymph nodes.



IMA = inferior mesenteric artery.

Cervical cancer and EC are midline cancers with bilateral lymphatic drainage. Sufficient mapping, therefore, implies detection of SLNs in each hemipelvis. False-negative procedures represent the major challenge in SLN mapping. However, adherence to an SLN algorithm significantly decreases the false-negative rate [10]. The SLN algorithm includes removal of any suspicious lymph nodes other than SLN, and side-specific PL in case of failed SLN mapping in a hemipelvis [10].

Ultra-staging

The SLNs were fixed in formalin, serially gross-sectioned at 2-mm intervals in a bread-loaf fashion or bivalved if less than 4 mm in any dimension. Three consecutive paraffin-embedded micro-sections, each 3-5 μm thick, were cut at four levels at 350 μm intervals. At all levels, the first micro-section was stained with routine HE staining, the second section was used for immunohistochemical staining for cytokeratin AE1/AE3, and the third section was available for additional analysis. All centres were introduced to the protocol by the same pathologist (DS).

Data managing

The project is associated with the Open Patient Data Explorative Network, which allows encrypted online data entry through a shared Research Electronic Data Capture [14] database. Data were handled, processed and archived according to the guidelines of the Danish Data Protection Agency. The cumulated detection rates were conducted using STATA version 16.0. All participants signed an informed consent form.

Trial registration: The study was approved by the Danish Data Protection Agency (R. no. 15/52037). The SENTIREC studies including this pilot study are registered with clinicaltrials.gov (NCT02825355 and NCT02820506).

RESULTS

Four centres and 14 surgeons were included. They performed a total of 140 procedures. The median number of procedures performed was 32 (range: 30-46). The total SLN detection rate was 91.3% with unilateral SLN

detection in 22.5% and bilateral SLN detection in 68.8% of the women (Table 1). The median number of identified SLNs was two (range: 0-7). The majority of SLNs were identified at the external iliac (33.3%) and the obturator fossa (31.9%) regions, whereas 8.6% of the SLNs were identified outside the standard PL area (Figure 2).

TABLE 1 Clinical characteristics and sentinel lymph node detection rates.

Included women, n	
Age, median (range), yrs	61 (24-85)
BMI, median (range), kg/m ²	27 (17-46)
<i>Cancer, n (%)</i>	
Cervical:	
Low-risk: tumour ≤ 2 cm	34 (56)
High-risk: tumour > 2 cm	27 (44)
Subtotal	61
Final FIGO 2009 cancer stage:	
IAI	2
IBI	54
IB2	2
IIA1	3
Endometrial:	
Low-intermediate risk	49 (62)
High risk	30 (38)
Subtotal	79
Final FIGO cancer stage: ^a	
IA	41
IB	16
II	7
III	13
IVA	2
<i>Sentinel lymph node</i>	
Procedure completed, n (%):	
Yes	138 (98.6)
No	2 ^b (1.4)
Detection nationally, n (%):	
No detection	6 (4.3)
Presumed sentinel node detection, pathology without lymphoid tissue	6 (4.3)
Unilateral sentinel node detection	31 (22.5)
Bilateral sentinel node detection	95 (68.8)
Total sentinel node detection (unilateral + bilateral)	126 (91.3)
Total detection: unilateral + bilateral per centre, %:	
Odense University Hospital	93.3
Rigshospitalet	90.0
Herlev Hospital	83.3
Aarhus University Hospital	97.0
Nodes per patient, median (range), n	2 (0-7)

FIGO = International Federation of Gynaecology and Obstetrics.

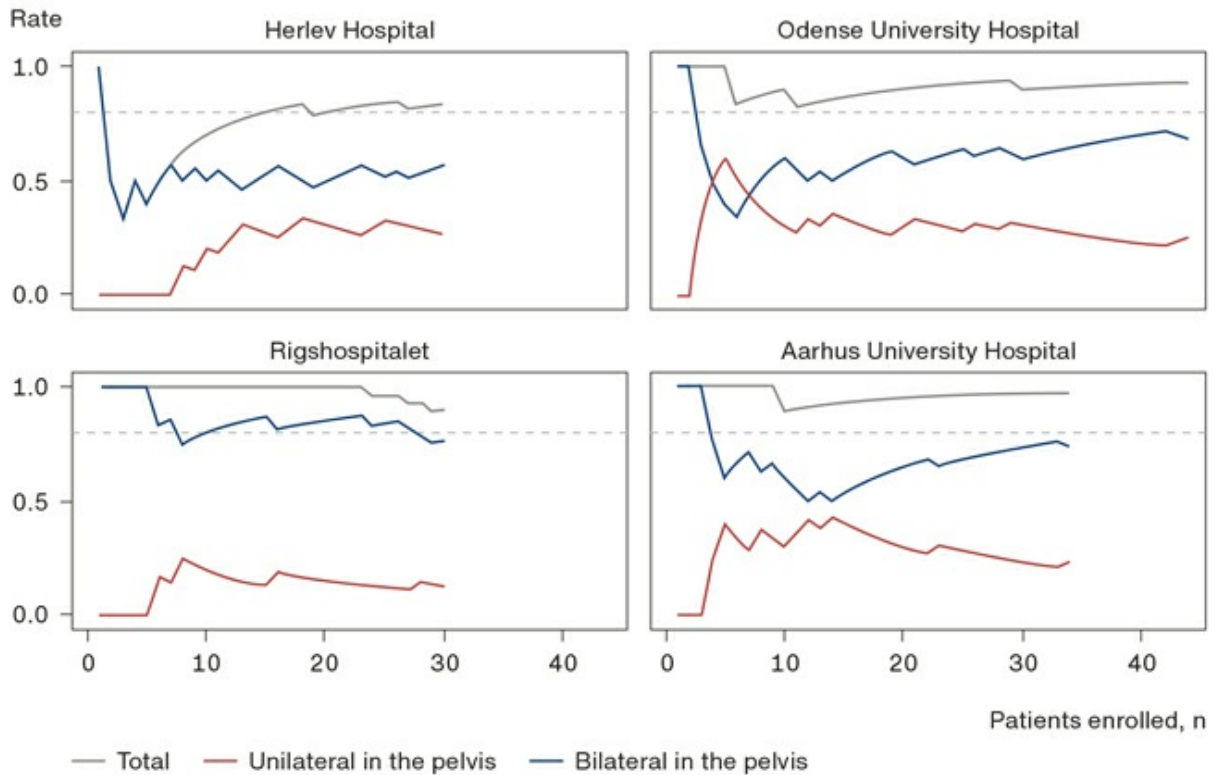
a) All women were included with presumed stage I-II, final stage from pathological examination.

b) No detection due to problems with the fluorescence camera in the robot.

The cumulated detection rates per centre are shown in Figure 3. At the three largest centres, the cumulated total detection rates were high and above 80% throughout the enrolment period. At the smaller centre, the total detection rate rose with an increasing number of procedures until 20 procedures after which the total detection rate stabilised above 80%. It should be noted that Figure 3 shows an estimate of the true cumulated SLN

detection rate. Some of the changes may reflect sampling variation, as – for simplicity - we did not include confidence intervals in the figure.

FIGURE 3 Cumulated sentinel lymph node detection rates.



In two women, the SLN mapping procedure was not performed due to technical problems with the fluorescence camera. In six women, no SLNs were identified; and in another six women, the presumed removed SLN were so-called “empty packets” that did not contain lymphatic tissue on final pathology (Table 1).

In 19/140 women (13.6%), LNM were detected. One woman with LR CC had a micro-metastasis in a SLN. Six women with LIR EC had metastatic disease, all identified in a SLN, with 4/6 identified by ultra-staging only.

In the group of women with HR CC, six of seven women with metastases were identified in SLNs and one metastasis was identified in the parametrium from the radical hysterectomy specimen. In women with HR EC, the SLN procedure identified two out of five cases with metastatic disease, whereas two women had a unilateral right-side failed SLN mapping, with metastases found in the right-side PL. One woman had successful bilateral SLN mapping and false-negative SLNs, since the metastasis was detected in a non-SLN lymph node.

DISCUSSION

The use of SLN mapping for CC and EC is gaining ground internationally. The technique has not been implemented systematically for CC and EC in Denmark due to lack of evidence of its oncological safety. In this study, the Danish gynaecological cancer centres were introduced to and systematically trained in the SLN mapping technique. An overall SLN detection rate of 91.3% is above the pre-set minimum goal of 80%. The SLN detection rate in our study is similar to detection rates reported from comparable studies [15, 16].

The cumulated SLN detection rates at each site were generally high throughout the study, and in three centres it

was above the pre-set criterion from the beginning of the inclusion period. This may be explained by the centralisation of gynaecological cancer surgery as from 2012 to few high-volume centres with surgeons who have passed advanced national and international surgical training programmes. Furthermore, for this pilot study and the future SENTIREC studies, a selected group of these surgeons was included and they were all familiar with the retroperitoneal spaces.

A recent study on SLN mapping in EC describes an increase in the odds of successful SLN mapping, which rises until 40 performed cases [17]. If this holds true, we can expect an even higher future detection rate at the Danish centres. In line with this, the cumulated SLN detection rates from two large centres (Odense and Aarhus) show a trend towards an increased total and bilateral detection rate with an increasing number of procedures (Figure 3). The curve from the smaller site (Herlev Hospital) clearly demonstrates an improvement in total detection rate until approx. 20 procedures, where it stabilises above 80%. At one centre (Rigshospitalet), the total detection rate was high throughout the inclusion period, though with a tendency towards a slight drop at the end of the enrolment period. However, this may be explained by the findings of two procedures with so-called “empty packets”, i.e. with no lymphatic tissue. This is a known troubling phenomenon during the surgical training of SLN mapping. In this pilot study, empty packets were found in six women. This has produced an increased awareness in the study group. All surgeons are now trained in a procedure with tactile control of all removed SLNs, as a lymph node is denser than lymphoid vessels or fatty tissue. The rate of empty packets is reported to decrease until it stabilises after 30 cases [18].

All detected LNM in women with LIR CC and EC were found in SLNs. The international literature has demonstrated that SLN mapping is safe for the identification of LNM in LR CC and LIR EC, with a higher detection of LNM reported than with conventional PL [19, 20]. This has led to a change in international guidelines, now recommending routine SLN mapping for these groups. Our results with an SLN detection rate of 91.3% and the finding of mainly low-volume LNM are reassuring and support the implementation of SLN mapping for LR CC and LIR EC in Denmark. In the revised DGCG guidelines, SLN mapping is recommended as a safe alternative although with continuous monitoring [12, 13].

All women with HR CC and EC had PL performed after SLN mapping according to the current national guidelines. In the HR CC group, there was no failed mapping. For HR EC, we observed one woman with false negative SLN and two cases with unilateral right-sided failed SLN mapping and metastases in the right side PL. Since the SLN algorithm was applied, the metastases in these two women were safely identified by the procedure. In line with this, a previous study has shown a decrease in false-negative procedures from 14.9% to 1.9% by applying the SLN algorithm [10]. The results for the women with HR EC raise attention about the importance of correct patient selection for SLN mapping. In the future SENTIREC studies, all women with HR CC and EC will have completion PL after SLN mapping along with the assessment of changes in lymphedema and quality of life. This is to investigate both the oncological safety of the SLN procedure and the impact of potential complications and late effects on the patient's life.

CONCLUSIONS

In this pilot study of SLN mapping in CC and EC, all centres demonstrated international-level detection rates. Surgeons from all centres showed a high proficiency during the pilot study and are thus eligible for participation in the future national multicentre SENTIREC studies to investigate the oncological safety besides benefits and harms of the SLN mapping procedure in women with CC and EC.

Correspondence Sarah Marie Bjørnholt. E-mail: bjornholt@clin.au.dk

*) Shared first authorship

Accepted 18 February 2021

Conflicts of interest Potential conflicts of interest have been declared. Disclosure forms provided by the authors are available with the article at ugeskriftet.dk/dmj

Cite this as Dan Med J 2021;68(4):A11200886

REFERENCES

1. Holloway RW, Gupta S, Stavitzski NM et al. Sentinel lymph node mapping with staging lymphadenectomy for patients with endometrial cancer increases the detection of metastasis. *Gynecol Oncol* 2016;141:206-10.
2. Rossi EC, Kowalski LD, Scalici J et al. A comparison of sentinel lymph node biopsy to lymphadenectomy for endometrial cancer staging (FIRES trial): a multicentre, prospective, cohort study. *Lancet Oncol* 2017;18:384-92.
3. Bats AS, Mathevet P, Buenerd A et al. The sentinel node technique detects unexpected drainage pathways and allows nodal ultrastaging in early cervical cancer: Insights from the multicenter prospective SENTICOL study. *Ann Surg Oncol* 2013;20:413-22.
4. Dansk Gynækologisk Cancer Gruppe. Retningslinier for visitation, diagnostik, behandling og kontrol af vulvacancer. Revideret 2018. [www.dgcg.dk/images/Grupper/Vulvacancergruppen/Retningslinier/Kap 5 Behandling og 5.1. Kirurgisk behandling af vulvacancer_LPF_THS.pdf](http://www.dgcg.dk/images/Grupper/Vulvacancergruppen/Retningslinier/Kap_5_Behandling_og_5.1_Kirurgisk_behandling_af_vulvacancer_LPF_THS.pdf) (27 Nov 2020).
5. Niebling MG, Pleijhuis RG, Bastiaannet E et al. A systematic review and meta-analyses of sentinel lymph node identification in breast cancer and melanoma, a plea for tracer mapping. *Eur J Surg Oncol* 2016;42:466-73.
6. Van Der Zee AGJ, Oonk MH, De Hullu JA et al. Sentinel node dissection is safe in the treatment of early-stage vulvar cancer. *J Clin Oncol* 2008;26:884-9.
7. Fuller AF, Elliott N, Kosloff C et al. Determinants of increased risk for recurrence in patients undergoing radical hysterectomy for stage IB and IIA carcinoma of the cervix. *Gynecol Oncol* 1989;33:34-9.
8. ASTEC study group, Kitchener H, Swart AMC, Qian Q et al. Efficacy of systematic pelvic lymphadenectomy in endometrial cancer (MRC ASTEC trial): a randomised study. *Lancet* 2009;373:125-36.
9. Eiriksson LR, Covens A. Sentinel lymph node mapping in cervical cancer: the future? *BJOG* 2012;119:129-33.
10. Barlin JN, Khoury-Collado F, Kim CH et al. The importance of applying a sentinel lymph node mapping algorithm in endometrial cancer staging: Beyond removal of blue nodes. *Gynecol Oncol* 2012;125:531-5.
11. Sedlis A, Bundy BN, Rotman MZ et al. A randomized trial of pelvic radiation therapy versus no further therapy in selected patients with stage IB carcinoma of the cervix after radical hysterectomy and pelvic lymphadenectomy: a gynecologic oncology group study. *Gynecol Oncol* 1999;73:177-83.
12. Dansk Gynækologisk Cancer Gruppe. Retningslinjer for visitation, diagnostik, behandling og kontrol af cervixcancer. Revideret 2017. www.dgcg.dk/images/Grupper/Cervixgruppen/Guidelines_2017/F._kirurgisk_behandling_ved_tidlig_cervixcancer-rev-nov.pdf (27 Nov 2020).
13. Dansk Gynækologisk Cancer Gruppe. Retningslinjer for visitation, diagnostik, behandling og kontrol af cancer corporis uteri. Revideret 2019. http://www.dgcg.dk/images/Grupper/Endometriegruppen/horing/Kap_3_Behandling_af_prim%C3%A6r_sygdom_240_419_uden_koder.pdf (27 Nov 2020).
14. Harris PA, Taylor R, Thielke R et al. Research electronic data capture (REDCap) - A metadata-driven methodology and workflow process for providing translational research informatics support. *J Biomed Inform* 2009;42:377-81.
15. Hagen B, Valla M, Aune G et al. Indocyanine green fluorescence imaging of lymph nodes during robotic-assisted laparoscopic operation for endometrial cancer. A prospective validation study using a sentinel lymph node surgical algorithm. *Gynecol Oncol* 2016;143:479-83.
16. Persson J, Salehi S, Bollino M et al. Pelvic Sentinel lymph node detection in High-Risk Endometrial Cancer (SHREC-trial) - the

final step towards a paradigm shift in surgical staging. *Eur J Cancer* 2019;116:77-85.

17. Tucker K, Staley SA, Gehrig PA et al. Defining the learning curve for successful staging with sentinel lymph node biopsy for endometrial cancer among surgeons at an academic institution. *Int J Gynecol Cancer* 2020;30:346-51.
18. Thomaier L, Jager L, Stone R et al. Risk of empty lymph node packets in sentinel lymph node mapping for endometrial cancer using indocyanine green. *Int J Gynecol Cancer* 2019;29:513-7.
19. Cibula D, Oonk MHM, Abu-Rustum NR. Sentinel lymph node biopsy in the management of gynecologic cancer. *Curr Opin Obstet Gynecol* 2015;27:66-72.
20. Holloway RW, Abu-Rustum NR, Backes FJ et al. Sentinel lymph node mapping and staging in endometrial cancer: A Society of Gynecologic Oncology literature review with consensus recommendations. *Gynecol Oncol* 2017;146:405-15.